



A Increasing Vertical Dimension: Considerations and Steps in Reconstruction of the Severely Worn Dentition

Steven T. Cutbirth, DDS*

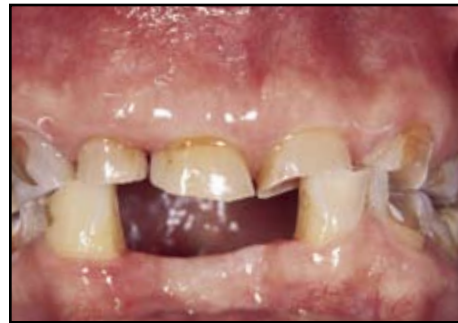

Figure A. Clinical example of severely worn dentition that results in a loss of vertical dimension of occlusion (VDO).

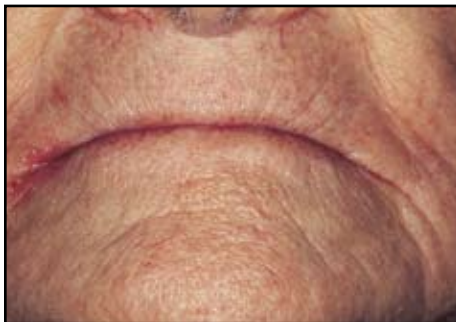

Figure B. Clinical view of patient who demonstrates signs of lost VDO. Note the down-turned lips when the patient is in closure.

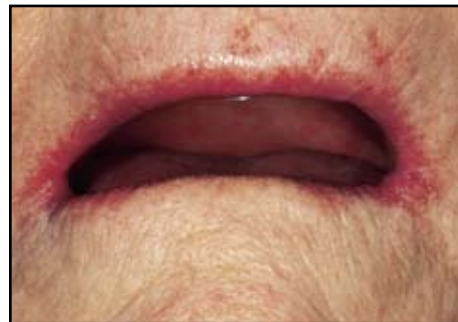

Figure C. Clinical appearance of angular cheilitis at the corner's of the patient's mouth, a sign of lost vertical dimension.

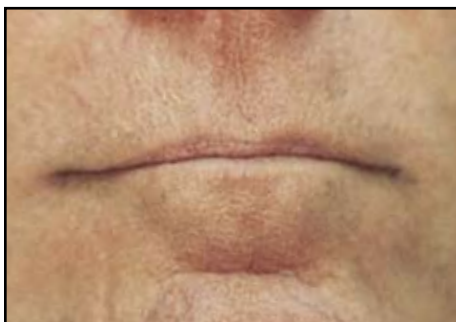

Figure D. Preoperative view of the patient demonstrates his vertically compressed appearance with his teeth closed.

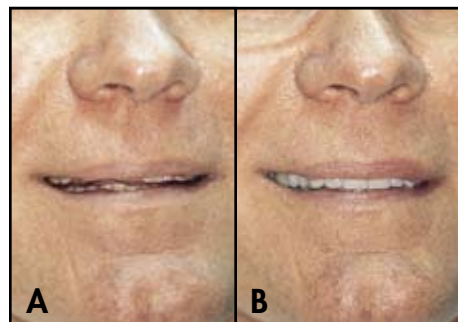


Figure E. Preoperative and post-operative view of the improved aesthetics and increased VDO achieved through the predictable restorative process.